

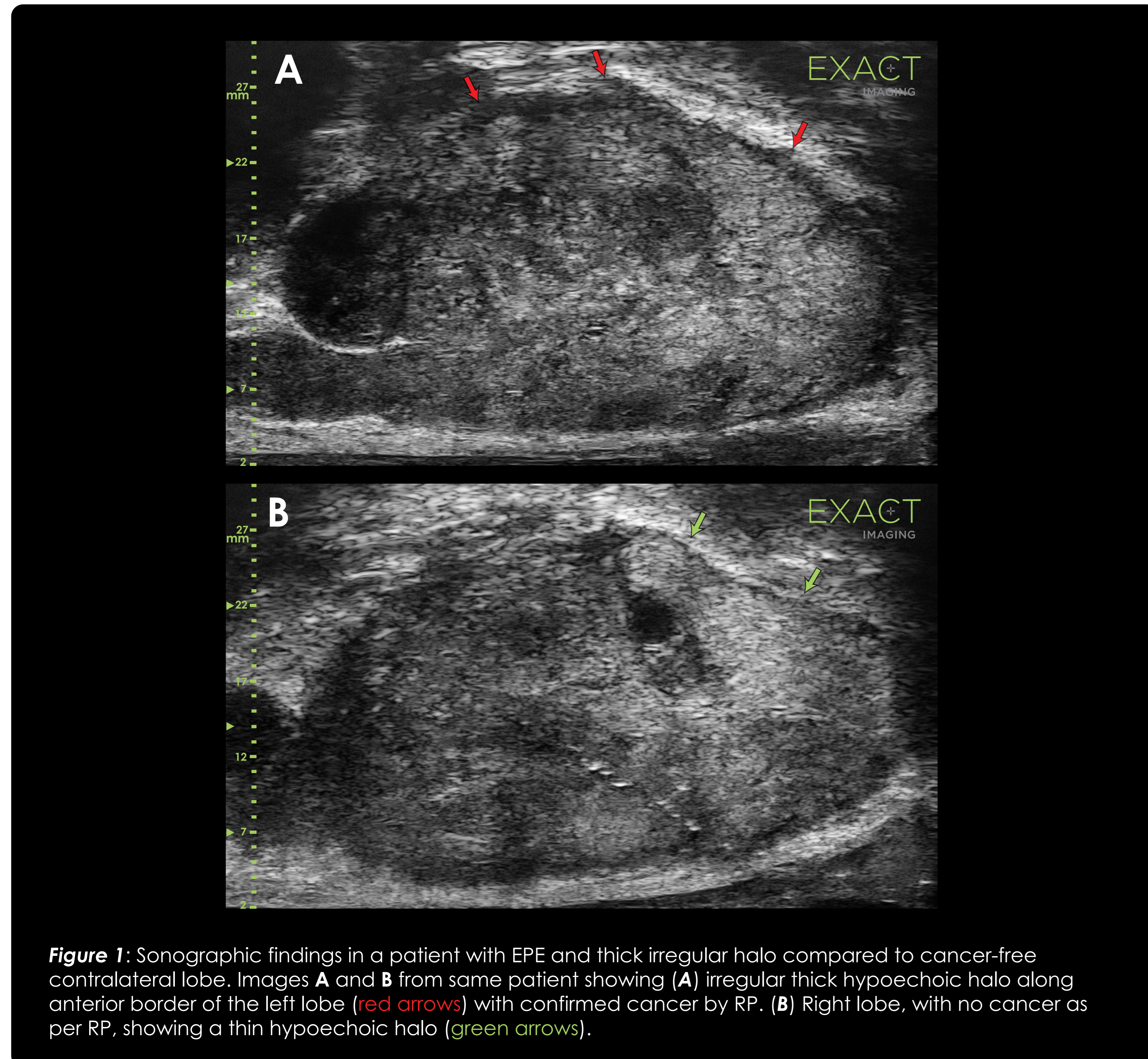
Can High-Resolution Micro-Ultrasound Detect Extra-Prostatic Extension? A New Sonographic Feature

INTRODUCTION

High-resolution **micro-ultrasound** is a novel **29 MHz** ultrasound modality enabling real-time targeted prostate biopsies. This increase in resolution allows visualization of tissue characteristics which can be correlated with clinically-significant indications. Micro-ultrasound technology has been shown to be more sensitive to detect prostate cancer than conventional ultrasound and a viable, cost-effective clinical alternative to MRI for guiding and targeting prostate biopsies.

OBJECTIVE

This work reviews a small case series of subjects who underwent radical prostatectomy (RP) following micro-ultrasound targeted biopsy and seeks to determine whether the micro-ultrasound images were predictive of extra-prostatic extension (EPE).



RESULTS:

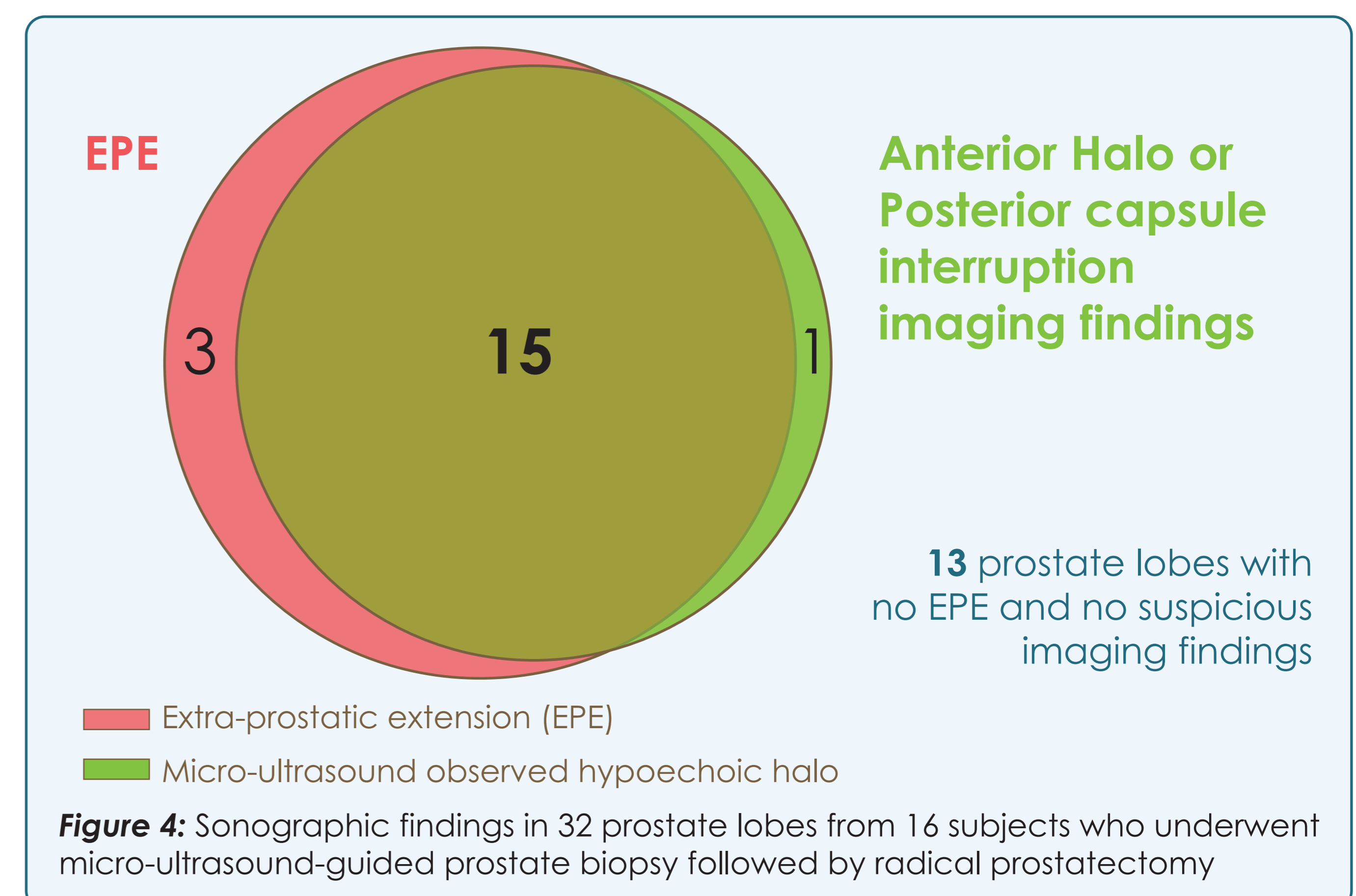
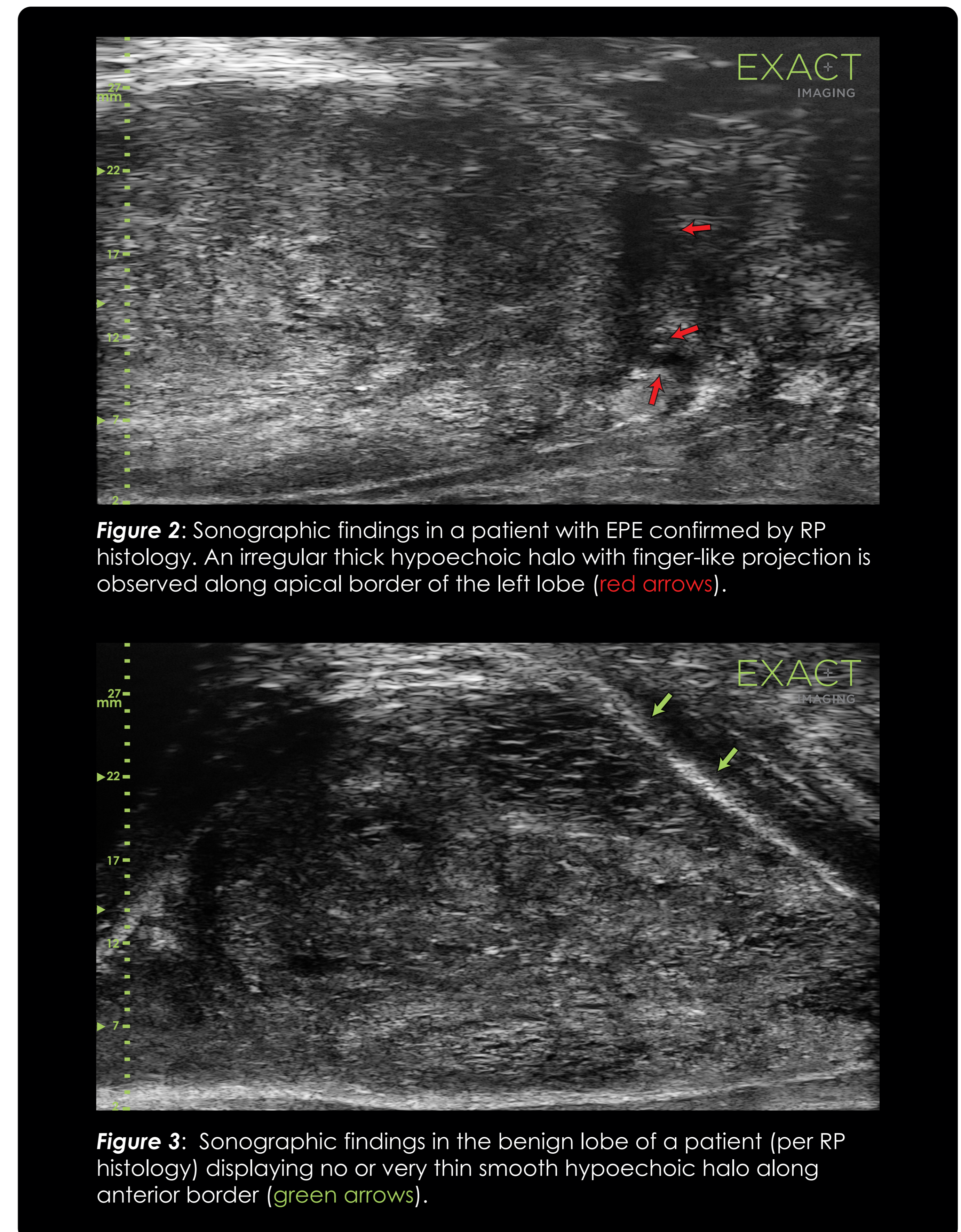
- In 15/18 prostate lobes with EPE, interruption of the posterior capsule or a hypoechoic halo surrounding the prostate along anterior and/or apical border was observed in the lobe with EPE.
- In 10/11 lobes with a hypoechoic halo, the halo was either thick, irregular or both.
- Upon examination of prostate lobes with benign findings, suspicious imaging findings were absent in 13/14.

Sensitivity	Specificity	NPV	PPV
15/18 (83%)	13/14 (93%)	13/16 (81%)	15/16 (94%)

Table 1: Sensitivity and specificity for observed posterior capsule interruption or thick/hypoechoic anterior/apical halo in 32 prostate lobes from subjects who underwent micro-ultrasound-guided prostate biopsy followed by radical prostatectomy. While the amount of data is limited, a high positive predictive value is observed, suggesting that this feature may be useful for presurgical planning.

METHODS:

- 16 subjects underwent RP following **micro-ultrasound targeted biopsy**.
- 18/32 prostate lobes had extra-prostatic extension (EPE) based on histopathology analysis of the RP specimen.
- **ExactVu™ Micro-Ultrasound** platform (Exact Imaging, Markham, Canada) was used to acquire images during real-time targeted biopsy procedure.
- Micro-ultrasound images were reviewed in all subjects to propose imaging features which might be predictive of EPE.



CONCLUSIONS:

- Micro-ultrasound imaging may be able to predict the presence of EPE.
- A “thick/irregular hypoechoic halo” on the anterior and/or apical prostate capsule appears to be increasingly correlated to the presence of EPE.
- More clinical data is required to corroborate this finding and more detailed examination of pathology specimens will be required to better interpret its meaning.

REFERENCES

1. Ghai S, Eure G, Fradet V, et al: *Assessing Cancer Risk on Novel 29 MHz Micro-Ultrasound Images of the Prostate: Creation of the Micro-Ultrasound Protocol for Prostate Risk Identification*. J. Urol. 2016; 196: 562–569.